ECT FOR PTSD



- Efficacy, mechanisms, and a hypothesis laid to rest

- Chittaranjan Andrade, MD
Senior Professor in Clinical Psychopharmacology and Neurotoxicology
National Institute of Mental Health and Neurosciences
Bangalore, India

2017 vs 2021

- 2017: Efficacy, mechanisms, and a hypothesis for new directions
- New clinical data, including RCTs
- 2021: Efficacy, mechanisms, and a hypothesis laid to rest

WHAT PTSD IS

- A trauma and stressor related disorder
  - Exposure to actual or threatened serious stressful event
  - Intrusive phenomena: memories, dreams, distress
  - Avoidance
  - Changes in cognition, mood related to the event
  - Hyperarousal
- Treatments, treatment response, clinical course
- PTSD is not a recognized indication for ECT
  - Reasons

ECT FOR PTSD

- Scope
  - Section 1: Efficacy of ECT in PTSD: Evidence
  - Section 2a: Possible clinical mechanisms
  - Section 2b: Possible neurohistological mechanisms
  - Section 3: Hypothesis for new direction for treatment

SECTION 1: EVIDENCE

- 2017
  - 3 case reports (4 cases)
  - 2 retrospective studies
  - 1 uncontrolled, prospective study
  - Plus one recent, innovative case report
- 2021
  - Additional case reports
  - 1 study on mechanisms
  - 3 retrospective studies
  - 2 RCTs

EFFICACY: CASE REPORT 1
(Helsley et al, Am J Psychiatry 1999)

- 35-year-old woman
- Severe medication- and psychotherapy-resistant, combat-related PTSD
- Substantial improvement with 6, thrice-weekly unilateral ECT

EFFICACY: CASE REPORT 2
(Hanretta and Malek-Ahmadi, J ECT 2006)

- 38-year-old woman
- Medication-refractory depression and PTSD.
- Complete remission from depression and PTSD with 8 bilateral ECT

EFFICACY: CASE REPORT 3

(Ozdemir et al, Bull Clinn Psychopharmacol 2013)

- Two men (age 40, 42 y) with combat-related PTSD and comorbid psychosis.
- Received 8-10 ECTs
- BPRS and CAPS scores each reduced by about a third.

EFFICACY: CASE REPORT 4
(Shore et al, Cureus 2021)

- 39 y male
- Severe, combat-related PTSD, MDD, TBI, suicidal ideation
- Severe trauma-related nightmares causing nightly awakenings
- Medication-refractory
- 6 RUL ECTs
- Depression remitted, PTSD attenuated by 40%, nightmares remitted

EFFICACY: CHART REVIEW 1
(Watts et al, J ECT 2007)

- 26 patients with major depressive episode and comorbid PTSD
- Received a mean of 9.7 RUL and bilateral ECT
- Substantial improvement in depression
- Small but statistically significant improvement in PTSD

EFFICACY: CHART REVIEW 2
(Watts and Groft, J ECT 2010)

- 32 patients with major depressive episode and comorbid PTSD
- Received a mean of 10 mostly RUL and bilateral ECT
- Modest improvement in depression
- Small but statistically significant improvement in PTSD

CHART REVIEWS: Comments

- In both studies, PTSD in slightly more than a third of patients was considered to have ‘responded’ to ECT.
- Both studies rated PTSD with an instrument that might have been insufficiently sensitive to identify improvement (Andrade et al, J ECT 2011)

Retrospective study
(Ahmadi et al, J Psychiatr Res 2018)

- MDD, (n=26), MDD+PTSD (n=10)
- Both groups showed small improvements in depression, PTSD, and global ratings across a year of monthly maintenance ECTs.

Retrospective study
(Kaster et al, Brain Stimul 2018)

- Retrospective study
- MDE (n=75) vs MDE + BPD/PTSD (n=75)
- Mean,10-11 ECTs in one or more courses
- Both groups improved but the groups with comorbidity improved less

Retrospective study
(Ahmadi et al, Depression Anxiety 201)

- 3485 patients with MDD+PTSD
- 92 treated with ECT, rest with antidepressants
- Patients treated with ECT showed greater improvement
- During 8 y f/y, suicide rates (2.2% vs 5.9%), mortality (9.7% vs 18%) were lower in ECT-treated patients

PROSPECTIVE STUDY: 1
(Margoob et al, Brain Stim 2010)

- 20 outpatients
  - Mean age, 38 years; 50% male
- Severe, chronic, refractory PTSD
  - Mean duration of illness, 3 years
  - Comorbid depression, if present, did not antedate PTSD
  - At least 4 failed antidepressant trials, 12 CBT sessions
- 6 twice-weekly bilateral ECT
- 3 (15%) drop outs

PROSPECTIVE STUDY: 2
(Margoob et al, Brain Stim 2010)

- ITT analysis:
  - CAPS scores decreased by 34%
  - Comparable improvement on re-experiencing, avoidance, numbing subscales of CAPS
  - MADRS scores decreased by 51%
  - Evidence of improvement by 3rd ECT (Day 10)
  - Improvement in CAPS independent of baseline MADRS
  - Improvement in CAPS independent of improvement in MADRS (r=0.42, NS)

PROSPECTIVE STUDY: 3
(Margoob et al, Brain Stim 2010)

- ITT analysis:
  - Response to ECT (30% decrease in CAPS): 70%
  - Remission (endpoint CAPS $\leq$20): 0%
- Post-ECT treatment gains maintained at 4-24 month follow up
  - Maintenance treatment with antidepressants
  - Functional improvements subjectively reported

ECT for PTSD: Pilot RCT
(Youssef et al, J ECT 2020)

- 5 patients with PTSD for whom ECT was indicated for treating depression
- Low (500 mA) vs standard (900 mA) 6x RUL ECT
- n=2 vs n=3
- Both groups showed modest improvement in PTSD ratings after a mean of 5 ECTs
- Not an RCT of ECT vs control intervention

Chittaranjan
Andrade

SECTION 2: HYPOTHETICAL MECHANISMS

- Clinical mechanisms
- Neurohistological mechanisms

MECHANISMS: CLINICAL

- Major depression is commonly comorbid with PTSD
- There is symptom overlap between depression and PTSD
- When depression improves with ECT, some PTSD symptoms could also improve
  - Not true improvement in PTSD

MECHANISMS: NEUROHISTOLOGICAL



- Nonspecific
  - Hippocampal/PFC neuroplasticity and learning adaptative skills
  - Hippocampal neuroplasticity and forgetting
- Specific
  - Amygdalar neuroplasticity and forgetting

Chittaranjan
Andrade

HIPPOCAMPAL, PFC NEUROPLASTICITY: 1a

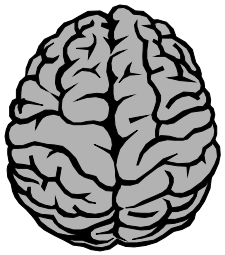

- ECS upregulates neuroplasticity in the hippocampus and in the PFC.
- In the hippocampus, there is an increase in neurogenesis, dendritic arborization, new synapse formation, and oligodendrogliosis
- These changes are evident even when cortisol, the stress hormone, is concurrently administered.
- Andrade and Rao, Indian J Psychiatry 2010; Smitha et al, J ECT 2014a&b

Chittaranjan
Andrade

HIPPOCAMPAL, PFC NEUROPLASTICITY: 1b

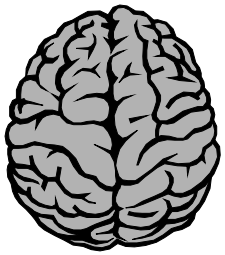

- ECS stimulates endothelial cell proliferation in the hippocampus, which change is independent of hypoxia related to ECS.
- ECS stimulates vascular and glial proliferation in the frontal cortex, as well.
- Some of the changes are dose-dependent; that is, greater with higher ECS dose, larger number of ECTs.
- Andrade and Rao, Indian J Psychiatry 2010; Smitha et al, J ECT 2014a&b

HIPPOCAMPAL, PFC NEUROPLASTICITY: 1c

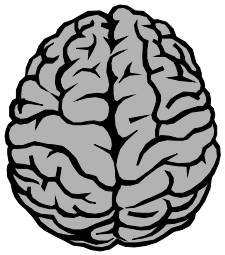

- Implications:
- Upregulated neuroplasticity may promote improved cognitive and hence adaptative functioning.
- Hence, assisting in recovery from conditions such as depression and PTSD.
- Andrade and Rao, Indian J Psychiatry 2010; Smitha et al, J ECT 2014a&b

Chittaranjan
Andrade

HIPPOCAMPAL NEUROPLASTICITY: 2a

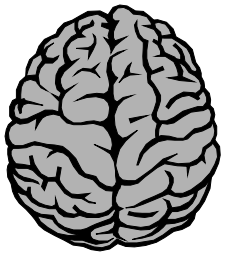

- ECS induces mossy fiber sprouting in the hippocampus (Gombos et al, Brain Res 1999, Lamont et al, Brain Res 2001).
- This change, along with other neuroplasticity changes, may result in formation of connections that disturb existing hippocampal networks.
- Possible result: interference with established memories, particularly recent memories.

Chittaranjan
Andrade

HIPPOCAMPAL NEUROPLASTICITY: 2b

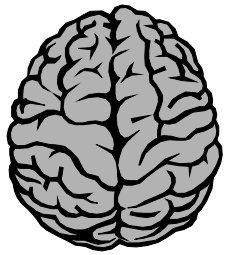

- Amnesiogenesis is undesirable in depressed patients
- In PTSD, it may help if stress-laden memories are weakened.
- In infant and adult rats, hippocampal neurogenesis (induced by exercise or fluoxetine) attenuates fear memories (Akers et al, Science 2014).

Chittaranjan Andrade

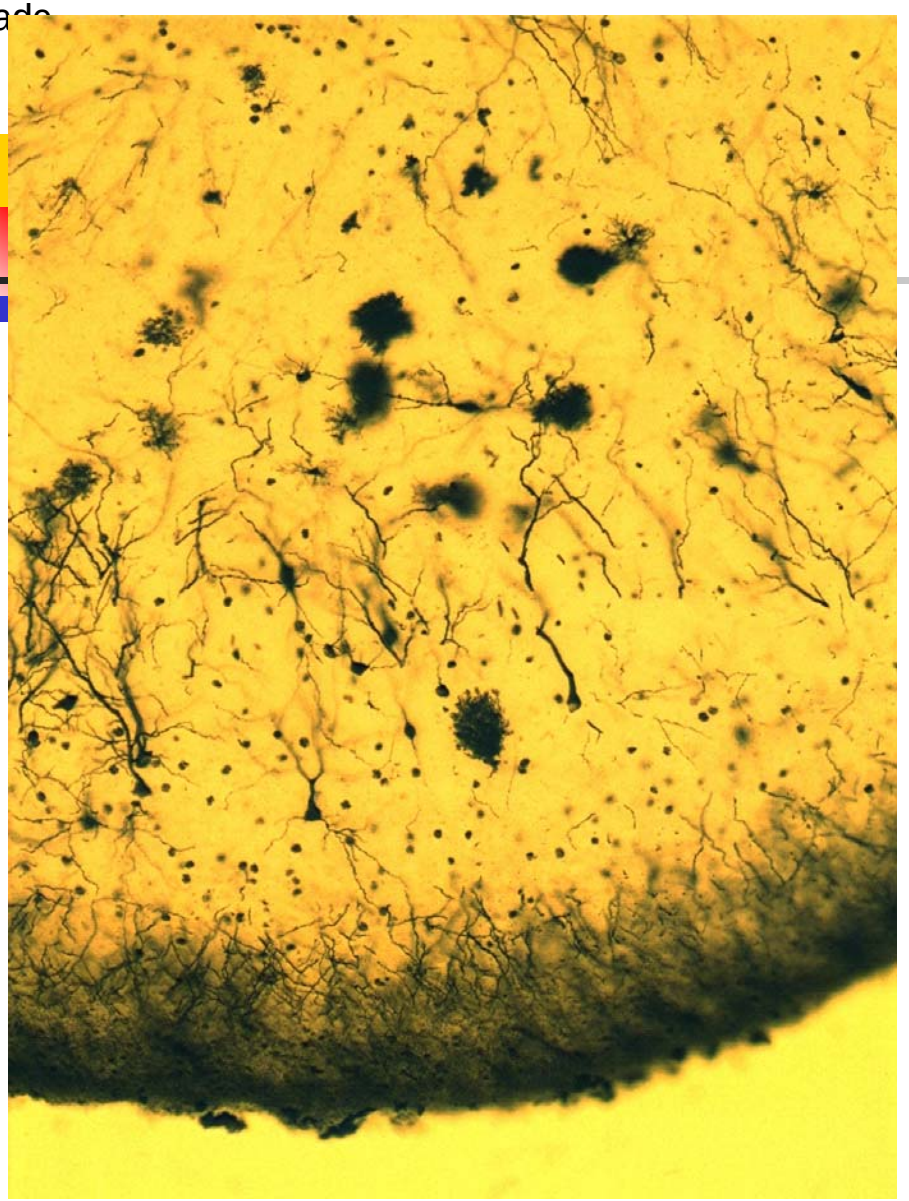

- Pyramidal neurons showing dendritic arborization.
- 6 once-daily sham ECS
- 10x magnification

Chittaranjan Andrade

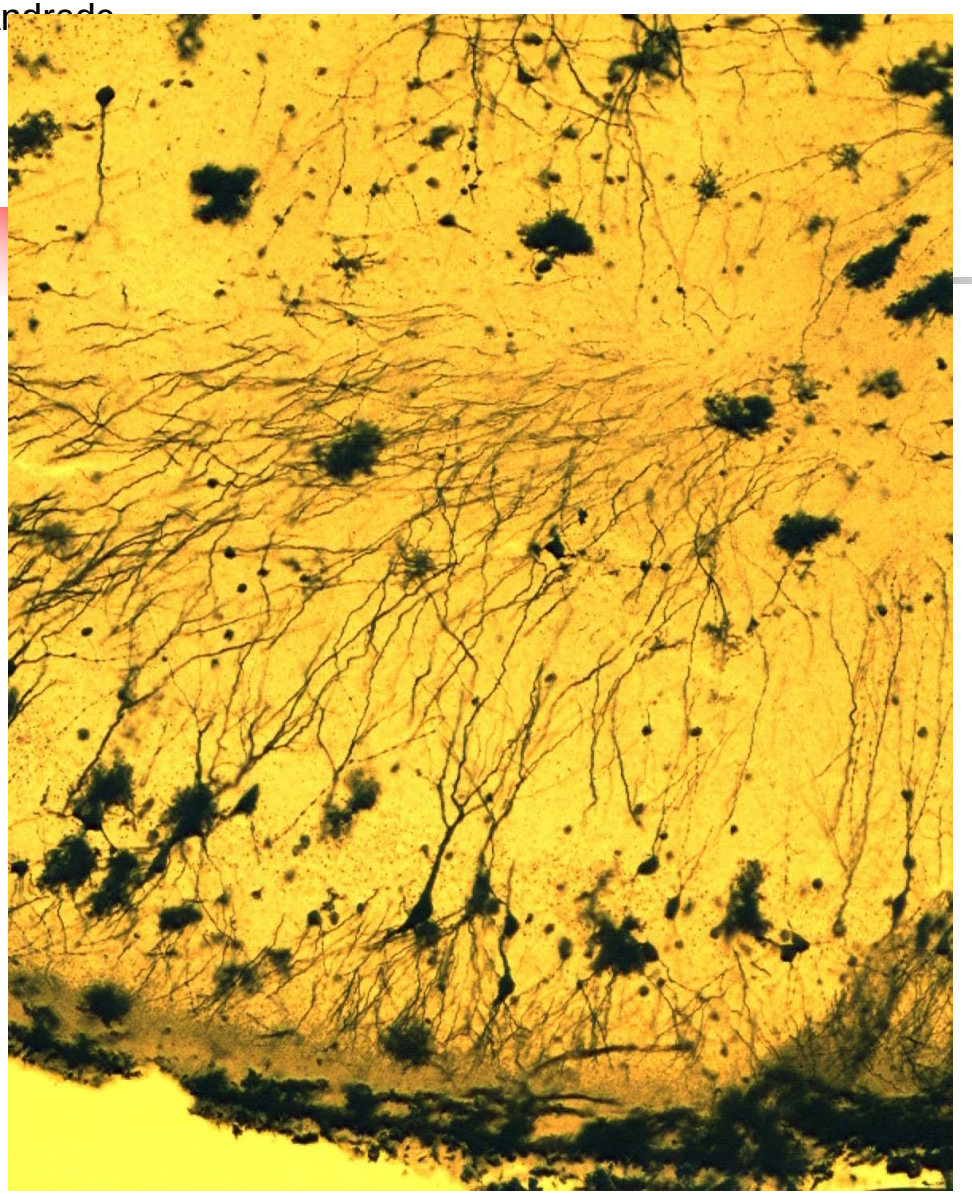

- Pyramidal neurons showing dendritic arborization.
- 6 once-daily 10 mC ECT
- 10x magnification

Chittaranjan
Andrade

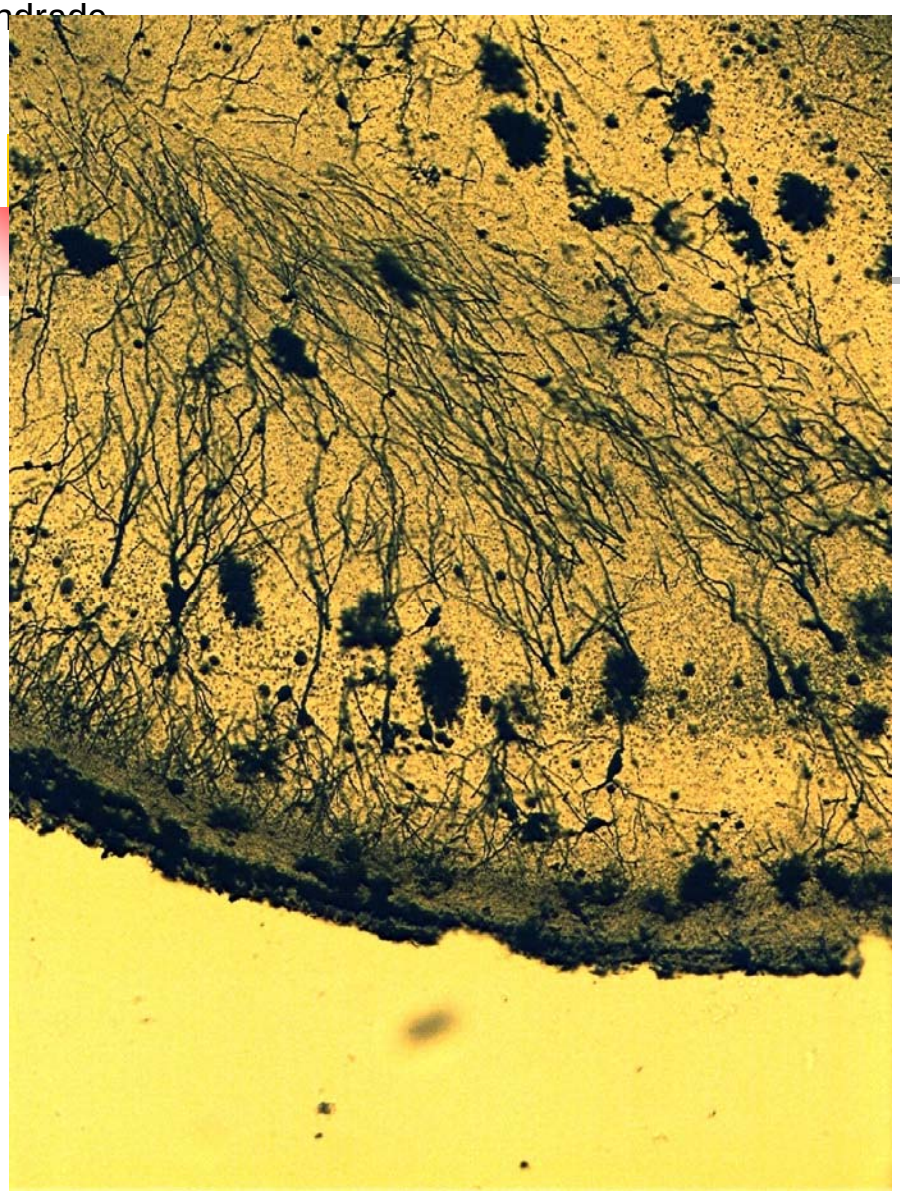

- Pyramidal neurons showing dendritic arborization.
- 6 once-daily 40 mC ECS
- 10x magnification

Chittaranjan Andrade

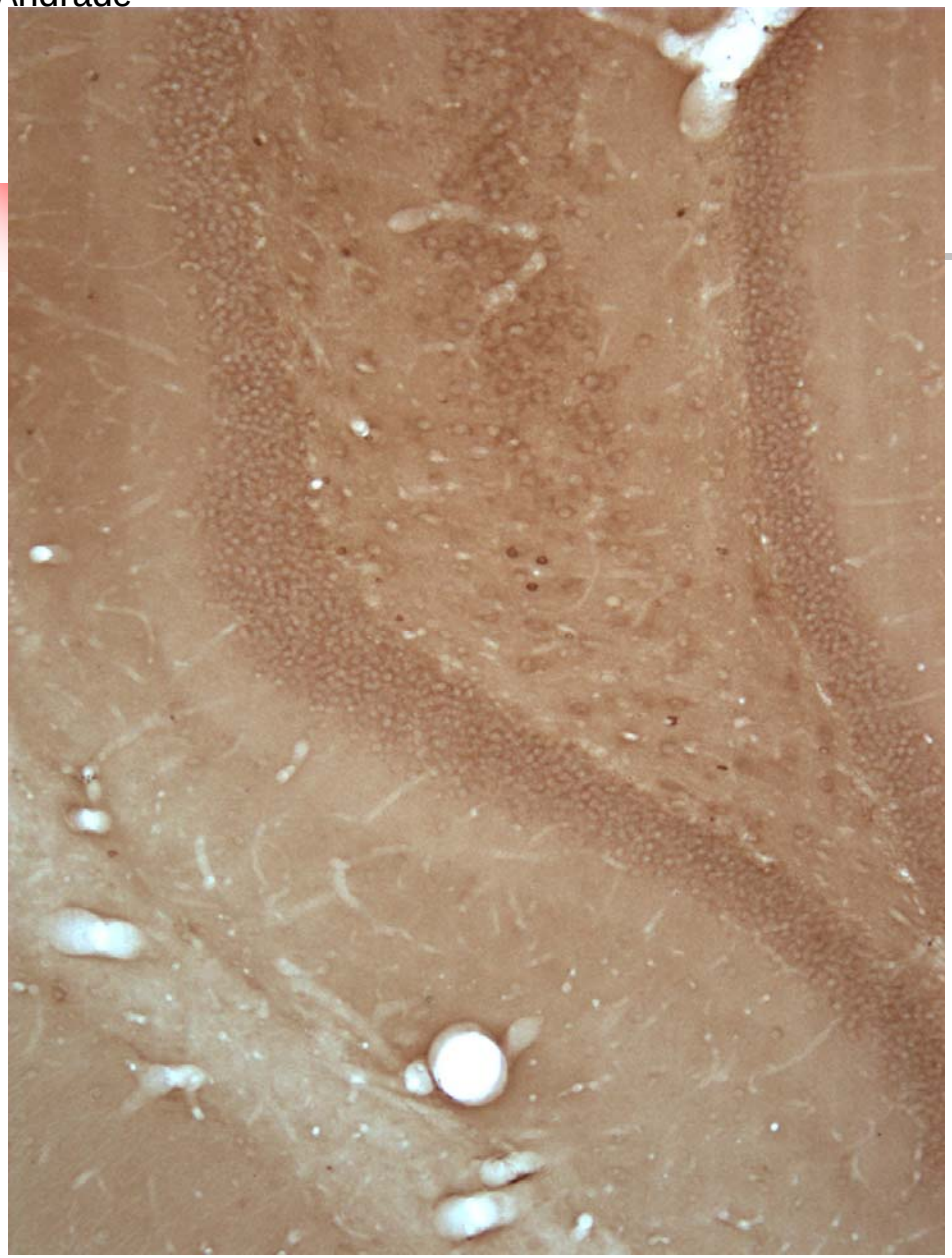

- BrdU stained new cells formed in the subgranular zone of the dentate gyrus.
- 6 once-daily sham ECS
- 40x magnification

Chittaranian
A

- BrdU stained new cells formed in the subgranular zone of the dentate gyrus.
- 6 once-daily 10 mC ECS
- 40x magnification

Chittaranjan
Andrade

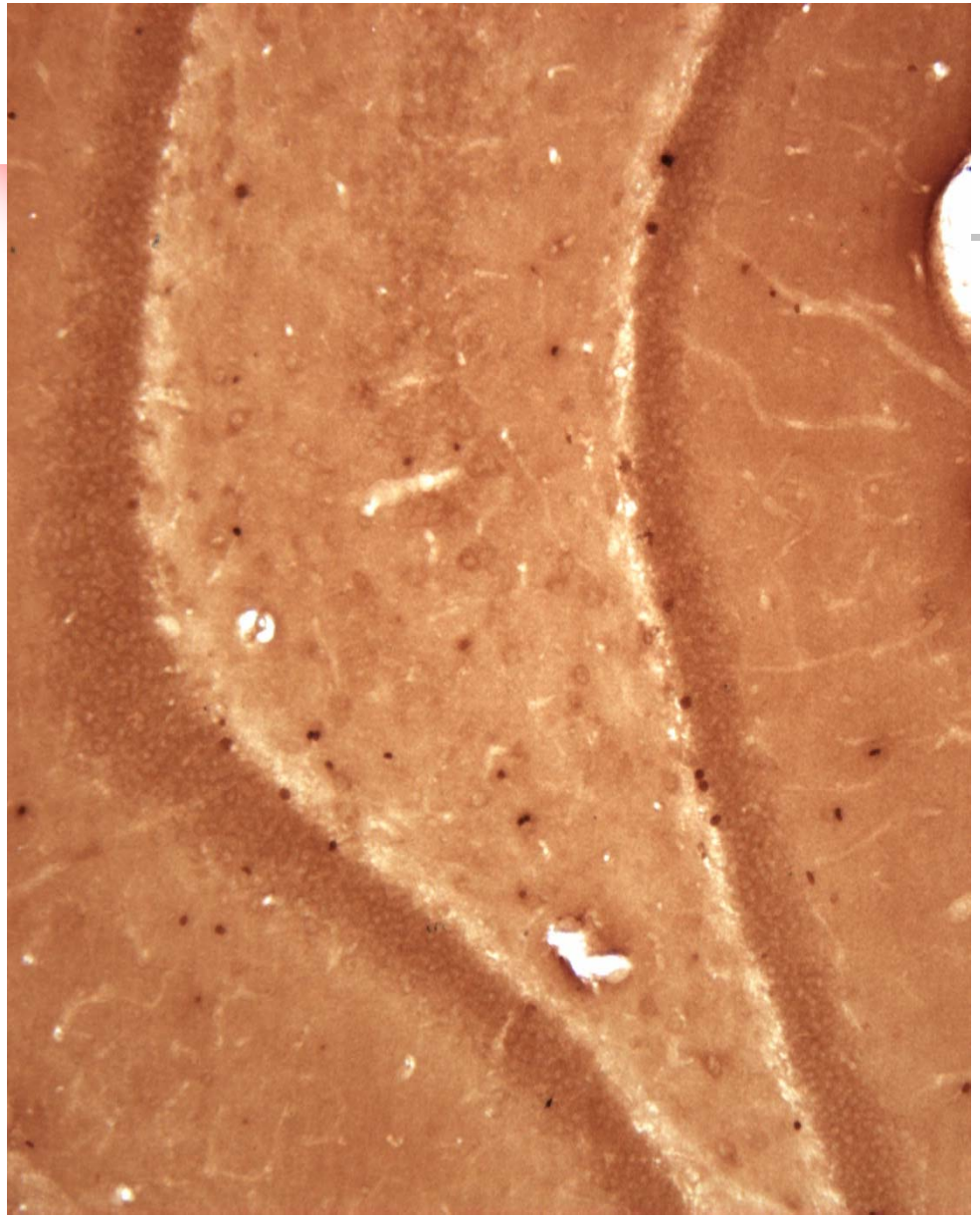

- BrdU stained new cells formed in the subgranular zone of the dentate gyrus.
- 6 once-daily 40 mC ECS
- 40x magnification

Chittaranjan
Andrade

AMYGDALAR NEUROPLASTICITY: 1

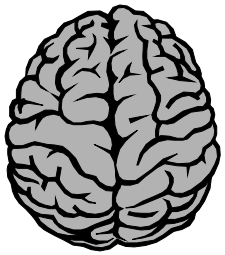

- Net effect
  - ECT downregulates amygdalar neuroplasticity
- ECS decreases
  - Dendritic arborization
  - Number of nodes
  - Excitatory synapses
- ECS increases
  - Inhibitory synapses

AMYGDALAR NEUROPLASTICITY: 2

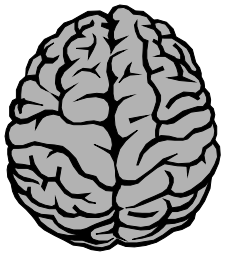

- The amygdala is involved in fear learning (Benarroch, Neurology 2015).
- The amydalar response to ECS suggests that ECT may weaken the negative affect attached to stress-laden memories (Andrade, J Clin Psychiatry 2014 a&b).

Chittaranjan
Andrade

AMYGDALA CHANGES AFTER 6 ECS: Sham, 10 mC, 60 mC

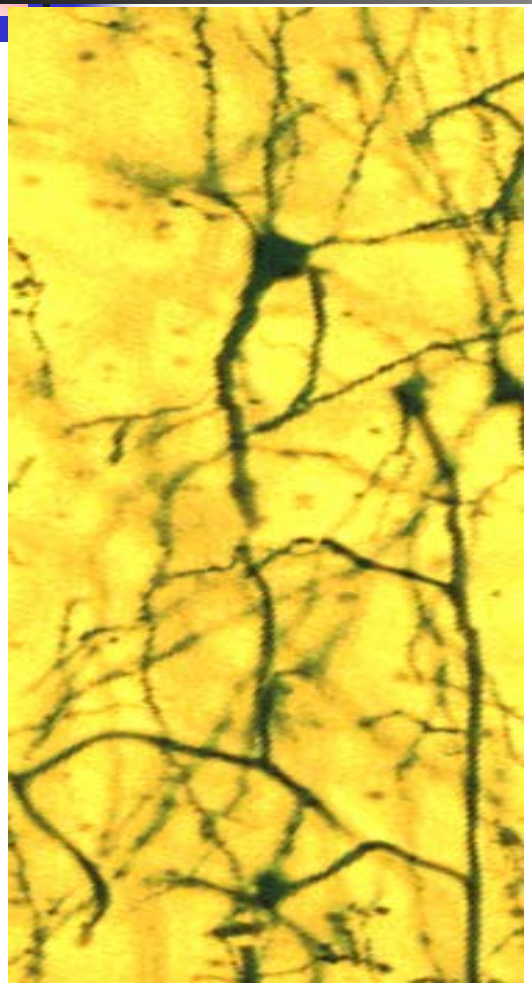

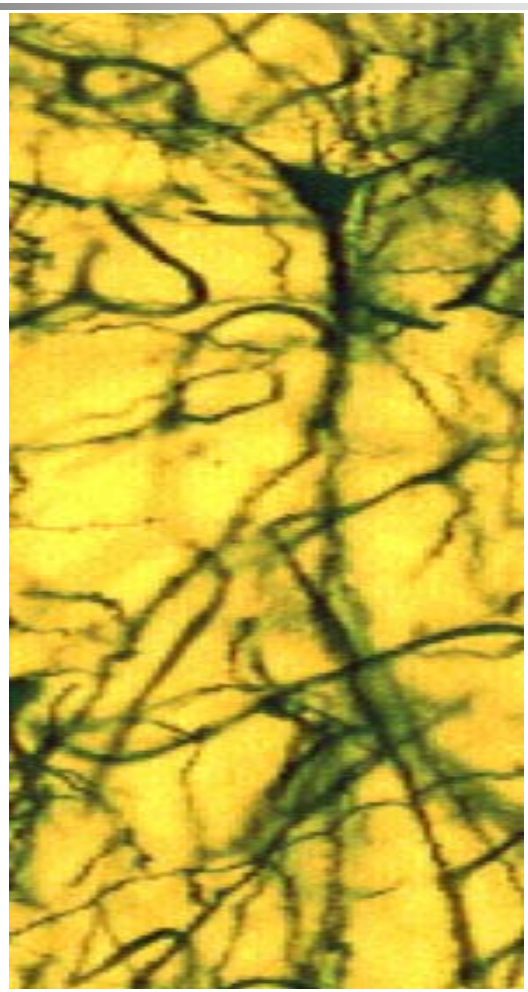

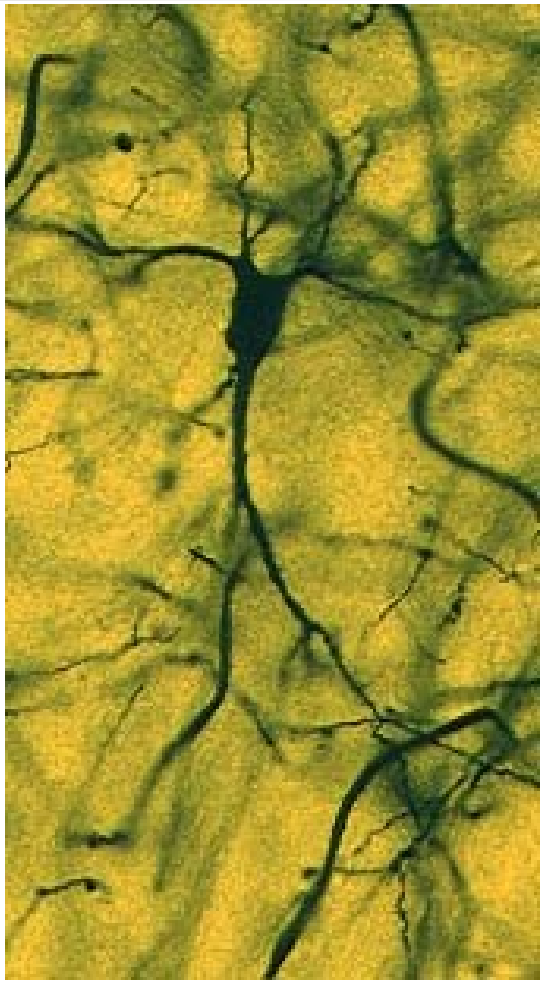

Chittaranjan
Andrade

AMYGDALA CHANGES AFTER 6 ECS: Control, 10 mC, 60 mC

- Squares/rectangles: Excitatory synapses
- Circles: Inhibitory synapses

- [Differentiation based on shape – circular vs elliptical or flattened]

Chittaranjan
Andrade

Sham ECS

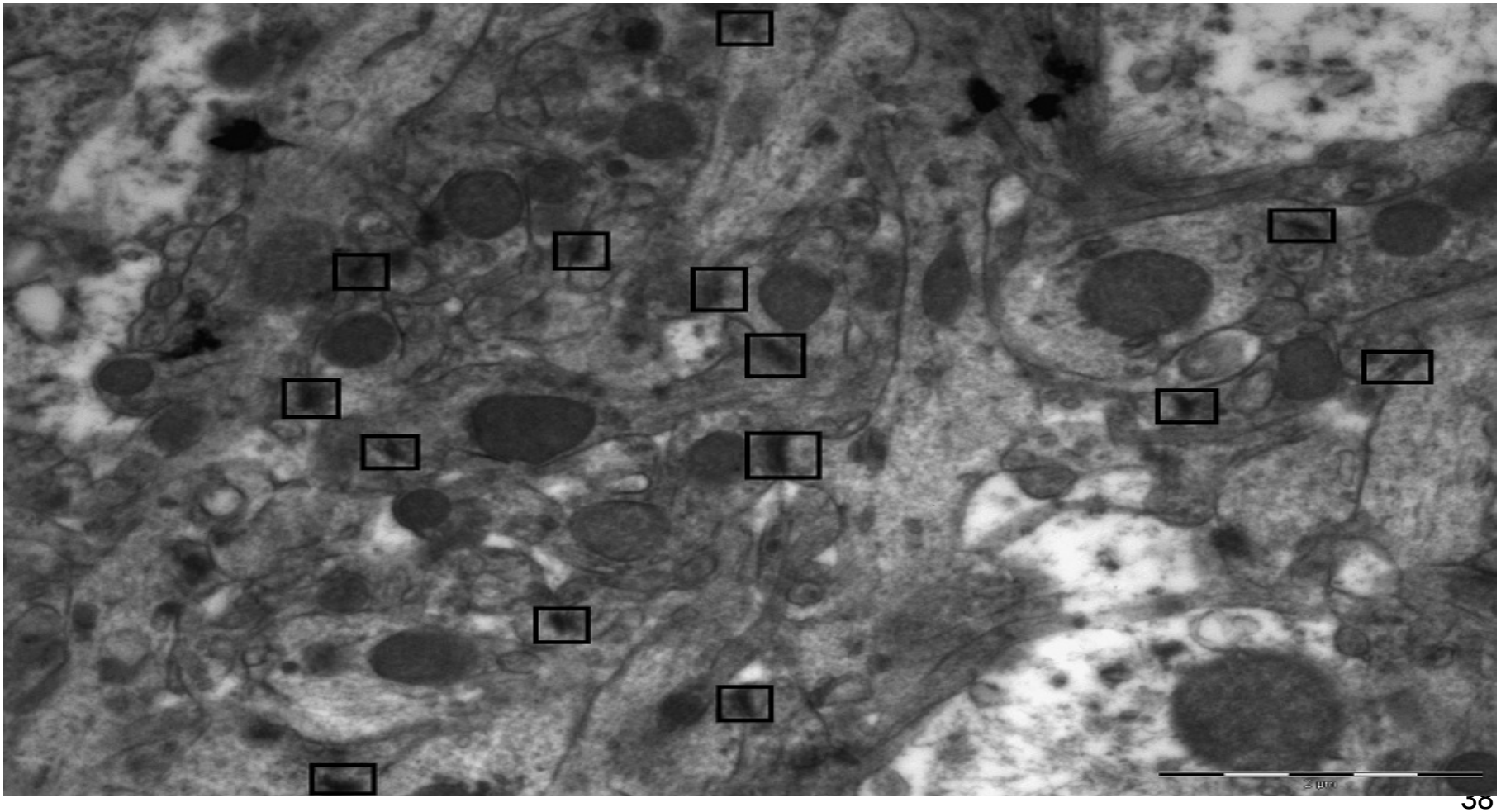

Chittaranjan
Andrade

10 mC ECS



Chittaranjan
Andrade

60 mC ECS

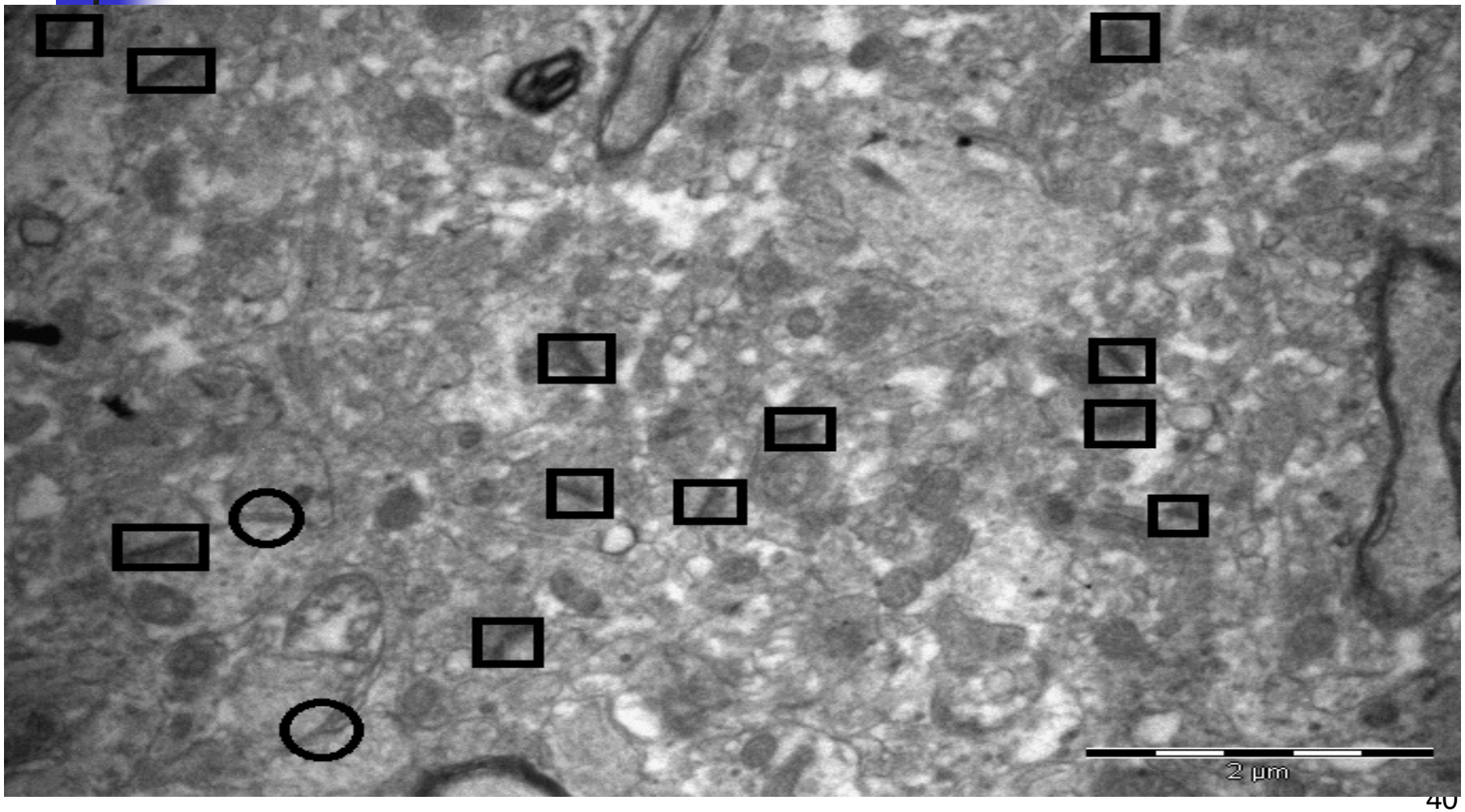

MDD: ECT AND THE AMGYDALA fMRI study: 1 (Redlich et al, Psychol Med 2017)

- Antidepressant (n=23), ECT (n=24) and healthy control (n=22) groups
- Pre-post, 6-week non-randomized study design
- Pre-treatment, both patient groups:
  - Increased amygdalar reactivity to sad faces
- Post treatment, both patient groups:
  - Reduced amygdalar reactivity to sad faces.
  - Decreased amygdalar activity was associated with symptomatic improvement (significant with ECT, trend with medication)

MDD: ECT AND THE AMGYDALA fMRI study: 2 (Redlich et al, Psychol Med 2017)

- Amygdala as the seat of fear learning
- Implications of the findings:
  - ECT, antidepressants may dampen emotional associations with anxiogenic memories
- Findings support the use of both ECT and ADs for both depression and PTSD.
- Limitations:
  - ECT patients also received antidepressants
  - Generalization from a lab experiment to real life events

SECTION 3:HYPOTHESIS FOR NEW DIRECTIONS IN TREATMENT

- Using ECT as a tool to disrupt specific memories

MEMORY IS LABILE

- Animal and human data show that when memories are awakened, they are transiently labile and can spontaneously distort or weaken before they are reconsolidated.
  - Examples from everyday life
  - Not applicable to rehearsing
- Weakening can be effected by the same agents that can impair the acquisition of new memories.
  - E.g. drugs, ECT
- de Beukelaar et al, Cortex 2014; Bjorkstrand et al, PLoS One 2015)

Chittaranjan
Andrade

USE OF ECT TO INACTIVATE SPECIFIC MEMORIES: Findings

- A single ECT administered immediately after the activation of a (recently created, laboratory-type) unpleasant memory can weaken that memory.
- Evident when that memory is tested one day (but not one hour) later.
- ECT does not disturb memories that are not reactivated immediately before the treatment.
- Kroes et al, Nature Neurosci 2014
- Implications for patients with PTSD

Chittaranjan
Andrade

USE OF ECT TO INACTIVATE MEMORIES: Challenges

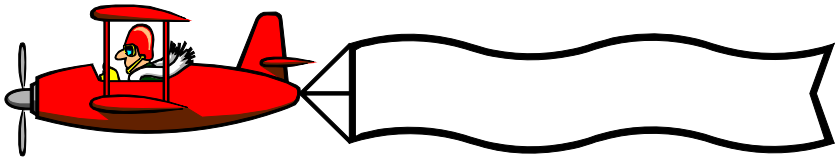

- PTSD memories are real, not laboratory-created.
- PTSD memories are longstanding, not recent.
- PTSD memories are well-rehearsed

TESTING THE HYPOTHESIS: Case report: 1

- Gahr et al, J Neuropsychiatry Clin Neurosci 2014
- 47-year old male
- 7-year h/o antidepressant- and CBT-refractory PTSD related to traffic accident, childhood sexual abuse
- Comorbid severe major depressive episode
- Treatment: 8 RUL ECT, thrice-weekly

TESTING THE HYPOTHESIS: Case report: 2

- Before each ECT, he was asked to recall the accident and to describe his recollections.
- The duration of reactivation was about 10 min
- The ECT procedure commenced 10 min later.
- Depression and PTSD both improved.
- After the ECT course, recall of the accident memories was much weakened and PTSD symptoms related thereto were attenuated.
- CSA memories, PTSD symptoms persisted.

TESTING THE HYPOTHESIS: Case report: 3

- Usual ECT-induced amnestic mechanisms
  - Show a temporal gradient
  - Lack specificity for an event
- Implication: Reactivation/reconsolidation interference, mediated by ECT, was responsible.

TESTING THE HYPOTHESIS: RCT: 1 (Tang et al, Brain Stimul 2021)

- 28 civilian women with severe depression and comorbid PTSD (25 completed)
- Randomized to reactivation of traumatic or non-traumatic memories using imagery created by a 125 word, 30 second audio script prior to each ECT.
- Number of ECTs, 10 (bilateral, 2.5) vs 14 (bilateral, 0)
- MDD, PTSD, both improved substantially
- No difference between groups in outcomes
- Pre-ECT traumatic memory reactivation does not improve PTSD outcomes after ECT.

TESTING THE HYPOTHESIS: RCT: 2 (Tang et al, Brain Stimul 2021)

- Limitations:
  - Whether reactivated memories were impaired was not tested (ECT was mostly RUL)
  - What if the memories were self-reactivated to an adequate extent instead of being reactivated through a 125-word, 30 second, standardized audio scrip?

USE OF ECT TO OBLITERATE TRAUMATIC MEMORIES IN PTSD

- Challenges: Several variables will need to be manipulated and studied
  - The nature of the memory that is activated
  - How it is reactivated
  - The extent to which it is activated
  - The duration for which it is activated
  - Reassurance provided, if any, during reactivation
  - Timing of the ECT with regard to the reactivation
  - Etc.

FINAL QUESTION

- Is ECT effective in PTSD with no comorbid depression?

ENFIN...

- That's it, folks; thanks for listening!